



CASE REPORT

## Sewing Needle as Foreign Body in Urethra of an Adolescent Boy: Case Report

Kashif Bangash<sup>1</sup>, Muhammad Naeem<sup>2</sup>, Hassan Mumtaz<sup>3</sup>, Aaliah Akhtar Hayat<sup>4</sup>, Mubashar Mazhar<sup>5</sup>, Shahzaib Ahmad<sup>6</sup>

<sup>1</sup>Consultant Urologist, KRL Hospital Islamabad; <sup>2</sup>Professor of Paediatric Surgery, KRL Hospital Islamabad; <sup>3</sup>Medical Officer, Clinical Research Center: Shifa International Hospital Islamabad; <sup>4</sup>Child Psychiatrist, Maternity & Children Hospital Makkah KSA; <sup>5</sup>Resident Urologist, KRL Hospital Islamabad; <sup>6</sup>Research Wing, King Edward Medical University, Lahore

### Abstract

Self-insertion of a foreign body in the urethra is an uncommon presentation clinically. The cases usually arise due to fulfillment of sexual desire, for recreation, play, or exploration, or the foreign body insertion may take place accidentally. We present a case of an adolescent boy with a foreign body urethra presenting to the emergency room with urinary retention, pain, and dysuria. Attending urologist suspected urethral stricture and ordered ultrasonography to investigate which turned out to be a sewing needle in his urethra. The patient was then enquired about the foreign body. He tried to self-dilate his urethra as he was experiencing lower urinary tract symptoms. The sewing needle was removed by endoscopy and he was administered with antibiotics and painkillers. The urethral foreign bodies may present with pain, dysuria, or urinary incontinence and these foreign bodies are mostly seen in the male population in the adolescent age group.

*Keywords:* endoscopy; foreign body; removal; urethra

*Received:* 4 August 2021; *Accepted after Revision:* 27 August 2021; *Published:* 8 September 2021

*Author for correspondence:* Hassan Mumtaz, Medical Officer, Clinical Research Center: Shifa International Hospital Islamabad. Email: [Hassanmumtaz.dr@gmail.com](mailto:Hassanmumtaz.dr@gmail.com)

*How to cite:* Bangash K, et al. Sewing Needle as Foreign Body in Urethra of an Adolescent Boy: Case Report. *J Ren Hepat Disord.* 2021;5(2): 17–19.

*Doi:* <https://doi.org/10.15586/jrenhep.v5i2.119>

*Copyright:* Bangash K, et al.

*License:* This open access article is licensed under Creative Commons Attribution 4.0 International (CC BY 4.0). <http://creativecommons.org/licenses/by/4.0>

### Introduction

Foreign body in genitourinary tract is seen rarely in urology clinics. Most of the cases of foreign body insertion arise from self-instrumentation following urinary tract pathology that is, strictures or urinary retention (1). Some cases arise from psychological conditions related to the mental health of the condition such as polyembolokoilamania (a psychiatric illness associated with insertion of foreign bodies in the body orifices for sexual gratification), intoxication, delusional

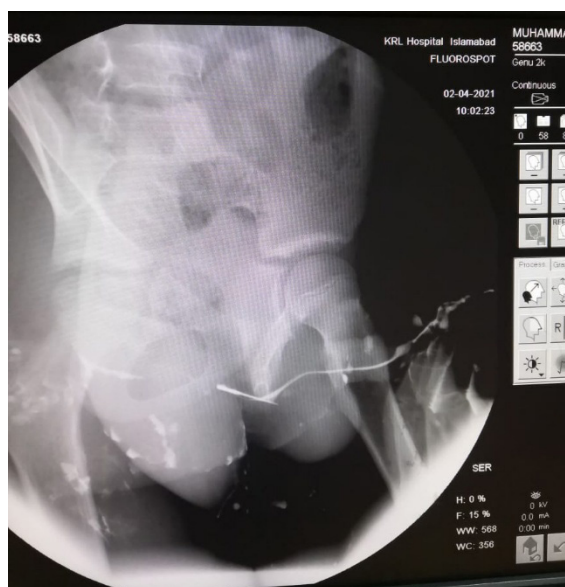
parasitosis, or autoeroticism (2). The most common cause of urethral foreign body insertion is inquisitiveness/exploration in children. Foreign bodies like plastic wires, pins, nail scissor, open safety pins, wax or glue, electrical wires, screws, AAA battery, plastic cup, straws, cotton-tipped swab, seeds of olives, small wooden stick, or ballpoint pens have been reported as foreign bodies in urethra and bladder (3). We present a case of an 11-year-old boy with sewing needle in his urethra following self-instrumentation.

## Case Presentation

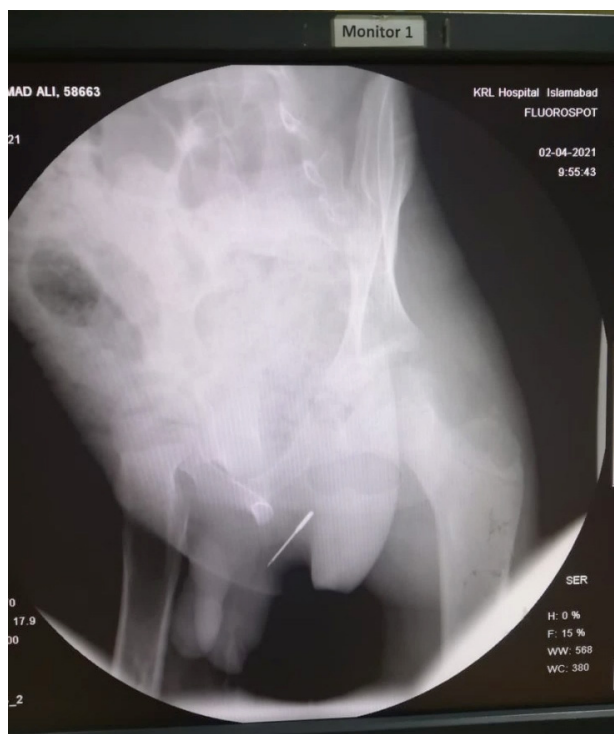An 11-year-old boy presented in the paediatric out-patient department of KRL Hospital Islamabad with poor urine flow, weak stream, and pain in pubic region for 3 weeks. The attending physician examined the patient and upon a detailed examination, genitourinary tract stricture was suspected. The patient was referred to the department of urology. The urologist ordered retrograde urethrography (RUG) to investigate the cause of urinary retention. The RUG showed a thin sharp opaque in the urethra. A sharp needle at the posterior urethra was found along with an incidental finding that is, fracture of the inferior ramus of pubis (Figures 1 and 2). Hence, foreign body urethra was diagnosed.

Upon enquiring the patient, he revealed that he was experiencing lower urinary tract symptoms. He tried to dilate his urethra using a sewing needle himself. One of the astonishing factors was that the patient inserted the blunt end of the sewing needle in the anterior urethra, and it went all the way to the posterior urethra. The child didn't try to remove the needle by manipulation and expected it to come out during micturition, but the needle didn't come out on urination.

Perineum was examined but no wound or laceration was found. External meatus was also normal. His serum electrolytes, complete blood count, renal function tests, and erythrocyte sedimentation rate were normal. To remove the foreign body, urologist planned endoscopy which showed pointed tip was embedded into the urethral wall and there was a difficulty in maneuvering the needle out of the urethral wall. Hence, the needle was laboriously picked up endoscopically,



**Figure 1:** Micturating urethrogram showing foreign body in posterior urethra.



**Figure 2:** Plain X-ray showing opaque foreign body.

and then moved backward. The needle was held from the pointed tip and brought out of the external urethral orifice. The needle was successfully retrieved without any damage to urethra or perineal structures (Figure 3).

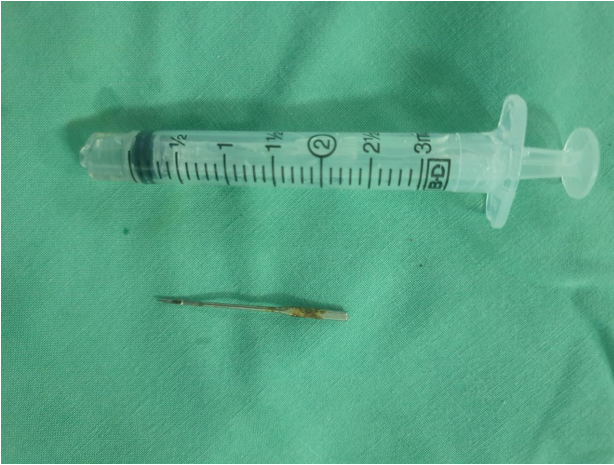After removal of the foreign body, the patient was kept under observation for 12 h. Prophylactic antibiotics and painkillers were prescribed to the patient for prevention of post-surgical infections and pain management. The patient had no obvious complications, so he was discharged.

Due to possible association of self-instrumentation with psychiatric illness, the child was referred for psychiatric evaluation.

## Discussion

Self-inflicted urethral foreign bodies are uncommon. These cases may present with diverse symptoms. The urethral foreign body may be difficult to remove depending on the nature, size, and position of the foreign body. Urethroscopy and plain X ray radiography are extremely helpful in evaluation and planning the surgery to remove the foreign body (4). In paediatric population, these cases must be referred for psychiatric evaluation such as fetishism & sadism (5).

The signs and symptoms of urethral foreign body are profoundly variable depending upon the manner of infliction



**Figure 3:** Sewing needle retrieved from the urethra endoscopically.

of the foreign body as well. The foreign body insertion may be motivated by sexual gratification and autoeroticism (6). The foreign body is removed in these patients, but there are chances that the patient may insert the foreign body again. So, the counselling and psychological treatment of the patient are vital prevention strategies in such cases (7).

In most of the cases with foreign body insertion, the removal strategy is the endoscopic removal as we did in this present case (8). But if the foreign body is difficult to remove, then open urethrostomy may be required to remove the foreign body (9).

Antibiotics and painkillers are recommended post-operatively to prevent secondary infections. If the patient complains of urinary incontinence following the foreign body removal, then urethroplasty may be indicated to relieve the patient's symptoms (10). The anticipated complications in these cases may be urinary tract infection, sepsis, laceration, ureteral stricture, or urinary incontinence (11, 12).

## Conclusion

The urethral foreign bodies may present with pain, dysuria, anuria, urinary incontinence, or urinary tract infections which are mostly seen in the adolescent age group. The endoscopic removal is a safe approach for removal of urethral foreign body.

## References

1. Prasad Ray R, Ghosh B, Pal DK. Urethral foreign body in an adolescent boy: report of two rare cases and review of literature.

- Int J Adolesc Med Health. 2015 Nov;27(4):463–5. PMID: 25781517. <http://dx.doi.org/10.1515/ijamh-2014-0057>
2. Khalili Fomeshi M, Ebrahimitabar F, Aghagani MMR, Mirabi P, Darzi M. Superglue self-insertion into the male urethra - A rare case report. *Caspian J Intern Med.* 2020 May;11(3):333–336. <http://dx.doi.org/10.22088/cjim.11.3.333>. PMID: 32874443; PMCID: PMC7442466.
3. Palmer CJ, Houlihan M, Psutka SP, Ellis KA, Vidal P, Hollowell CM. Urethral foreign bodies: clinical presentation and management. *Urology.* 2016 Nov;97:257–260. <http://dx.doi.org/10.1016/j.urology.2016.05.045>. Epub 2016 May 31. PMID: 27261182.
4. Frier J, Nicholas E, Klawitter P. Case report: using point-of-care ultrasound as a tool to identify a urethral foreign body. *Clin Pract Cases Emerg Med.* 2021 Feb;5(1):39–42. <http://dx.doi.org/10.5811/cpcem.2020.10.49290>. PMID: 33560949; PMCID: PMC7872595.
5. Unruh BT, Nejad SH, Stern TW, Stern TA. Insertion of foreign bodies (polyembolokoilamania): underpinnings and management strategies. *Prim Care Companion CNS Disord.* 2012;14(1):PCC.11f01192. <http://dx.doi.org/10.4088/PCC.11f01192>. Epub 2012 Feb. 16. PMID: 22690353; PMCID: PMC3357565.
6. Bogdanović J, Sekulić V, Trivunić-Dajko S, Herin R. Re: Palmer et al. Urethral foreign bodies: clinical presentation and management (*Urology* 2016;97:257–260). *Urology.* 2017 Feb;100:256–258. <http://dx.doi.org/10.1016/j.urology.2016.07.049>. Epub 2016 Nov 2. PMID: 27816601.
7. Bello JO, Badmus KO, Babata AL, Bello HS. Polyembolokoilamania: self-insertion of transistor radio antenna in male urethra. *Niger Med J.* 2013 May;54(3):206–8. <http://dx.doi.org/10.4103/0300-1652.114578>. PMID: 23900734; PMCID: PMC3719250.
8. Rahman NU, Elliott SP, McAninch JW. Self-inflicted male urethral foreign body insertion: endoscopic management and complications. *BJU Int.* 2004 Nov;94(7):1051–3. <http://dx.doi.org/10.1111/j.1464-410X.2004.05103.x>. PMID: 15541127.
9. Crawford SB, Lowry D, Watts SH. Evaluation and management of urethral foreign bodies and description of a novel ultrasound-guided catheter-based extraction technique. *J Am Coll Emerg Physicians Open.* 2021 Mar 5;2(2):e12398. <http://dx.doi.org/10.1002/emp2.12398>. PMID: 33728419; PMCID: PMC7934071.
10. Al-Hakeem Y, Chung A, Chung B, Tse V. Substitution urethroplasty for the treatment of male urethral stricture: Outcomes in an Australian center. *Low Urin Tract Symptoms.* 2019 Sep;11(4):211–216. <http://dx.doi.org/10.1111/luts.12265>. Epub 2019 May 7. PMID: 31064032.
11. Forde JC, Casey RG, Grainger R. An unusual penpal: case report and literature review of posterior urethral injuries secondary to foreign body insertion. *Can J Urol.* 2009 Aug;16(4):4757–9. PMID: 19671232.
12. Amiroune D, Bouchikhi AA, Adawi F. Retained self-inserted foreign body into the urethra associated with sequela urethral stenosis: a case report. *J Med Case Rep.* 2014 Jul 5;8:244. <http://dx.doi.org/10.1186/1752-1947-8-244>. PMID: 24997473; PMCID: PMC4106200.